

The Lateral Supramalleolar Flap for Reconstruction of the Distal Leg and Foot

MAGDY ABD AL MOKTADER, M.D.; MONA HASSAN, M.D.; WAEL AYAD, M.D.; TAREK ELBANOBY, M.D. and ESSAM TAMAN, M.D.

The Department of Plastic and Reconstructive Surgery, Faculty of Medicine, Al-Azhar University.

ABSTRACT

We describe our experience and evaluate the reliability of, the lateral supramalleolar flap that was used in 16 patients for reconstruction of the distal leg and foot. There were 10 men and 6 women, age range 2-60 years. The causes of the skin defects included trauma, deep burn and diabetic ulcer. Sites of the defects were the lower leg, over the malleoli and in front of the ankle. Fourteen flaps survived and provided satisfactory coverage of the defect. Two flaps showed partial necrosis and were treated conservatively. We think that the lateral supra-malleolar flaps a good way to reconstruct soft tissue defects of the lower extremity. It has a large skin paddle and a wide rotation arc.

INTRODUCTION

Reconstruction of soft tissue defects of the lower extremity is a common and challenging problem. Because of the limited availability of local tissue, particularly in the lower leg and foot, the use of distant flaps for covering those defects often looks necessary. Cross leg flaps have been used in the past, but have few indication nowadays. Free tissue transfer may offer the best surgical option in most cases, use of free flaps, however, is always associated with risk at the anastomosis. As well as the free transfer techniques tack long time. Axial pedicle flaps harvested from the leg can often provide good and safe reconstructive solutions with relatively simpler techniques [1].

The lateral supramalleolar flap is one of the series of flaps that has been described in the last decades and are based on the secondary arteries of the limb. It is a fasciocutaneous flap that is raised on the lateral aspect of the lower leg and it is usually used as a distally-based pedicle flap for covering defects on the lower third of the leg and the foot [2].

Surgical anatomy:

The lateral supramalleolar flap is a fasciocutaneous flap raised on the distal perforating branch of the peroneal artery as its vascular pedicle. Masquelet et al., showed that the perforating branch of the posterior peroneal artery consistently emerges from a groove between the tibia and the fibula, just proximal to the distal tibiofibular ligament and can be found 5cm above the lateral malleolus. It divides into a superficial (ascending) cutaneous and a deep descending branch shortly after perforating the interosseous membrane. The superficial cutaneous branch supplies a skin territory approximately 12.0-18.0cm in length and 9.0cm in width, corresponding to an area on the lower half of the leg from the tibial crest to the posterior margin of the fibula [3].

MATERIAL AND METHODS

Sixteen patients with various defects of the distal leg and foot caused by different etiological factors were managed by lateral supramalleolar flap. A total of 16 patients admitted during the period of September' 2007 to May' 2009 with lower limb defect/wound with exposed bone (tibia/fibula) and/or in front of the ankle joint. The study was conducted in the department of Plastic Surgery, in Al-Azhar University Hospital.

The patients were submitted to a preoperative mapping study with echodoppler to identify the closest perforating vessels to the injury margin. Once perforating vessels topography was identified, these were outlined with a dermatographic pen. Based on this previous mapping, patches were designed on donor areas considering the longitudinal axis

of the main vessel, as well as the length and width required for covering the skin defect without tension.

Surgical technique:

The patient is placed supine with a roll or a pillow placed under the ipsilateral hip. Assessment of the defect is carried out and the size of the flap marked within the vascular territory. A hand-held Doppler probe can be used to locate the perforating branch, and its position is marked. A tourniquet is used during the dissection. The ulcer is excised and the defect thoroughly irrigated. The margins of the flap are then incised down to the deep fascia. The deep fascia is incised and the flap raised proximally to distally in the sub-fascial plane to locate the perforator. Once the perforator is located and preserved, the remainder of the flap is raised (Fig. 2). The flap is then rotated into the defect based on its vascular pedicle. A drain is placed under the flap and the flap can then be sutured in place. The donor can be closed directly if the width of the flap less than 3cm. Otherwise, A split-

thickness skin graft is harvested and secured onto the secondary defect (Figs. 1,2,3). The wounds are dressed [4].

RESULTS

The lateral supramalleolar flaps were performed in 16 cases from 2007 to 2009. Of these 10 were males and 6 were females. Ages ranged from 2 years to 60 years with an average of 38. The flaps were successful in 14 cases. The take of the skin graft on the donor defect was good in all cases.

Complications such as marginal necrosis of the flap were encountered in two cases and were treated conservatively. Active movement was encouraged after 1 month.

The follow-up period ranged from 1 to 3 years. In general, the texture, thickness and color of the flaps matched the surrounding, and patients were satisfied with the results. The thickness of the flap was suitable to cover the dorsum of the foot, medial and lateral malleoli (Figs. 1,2,3).

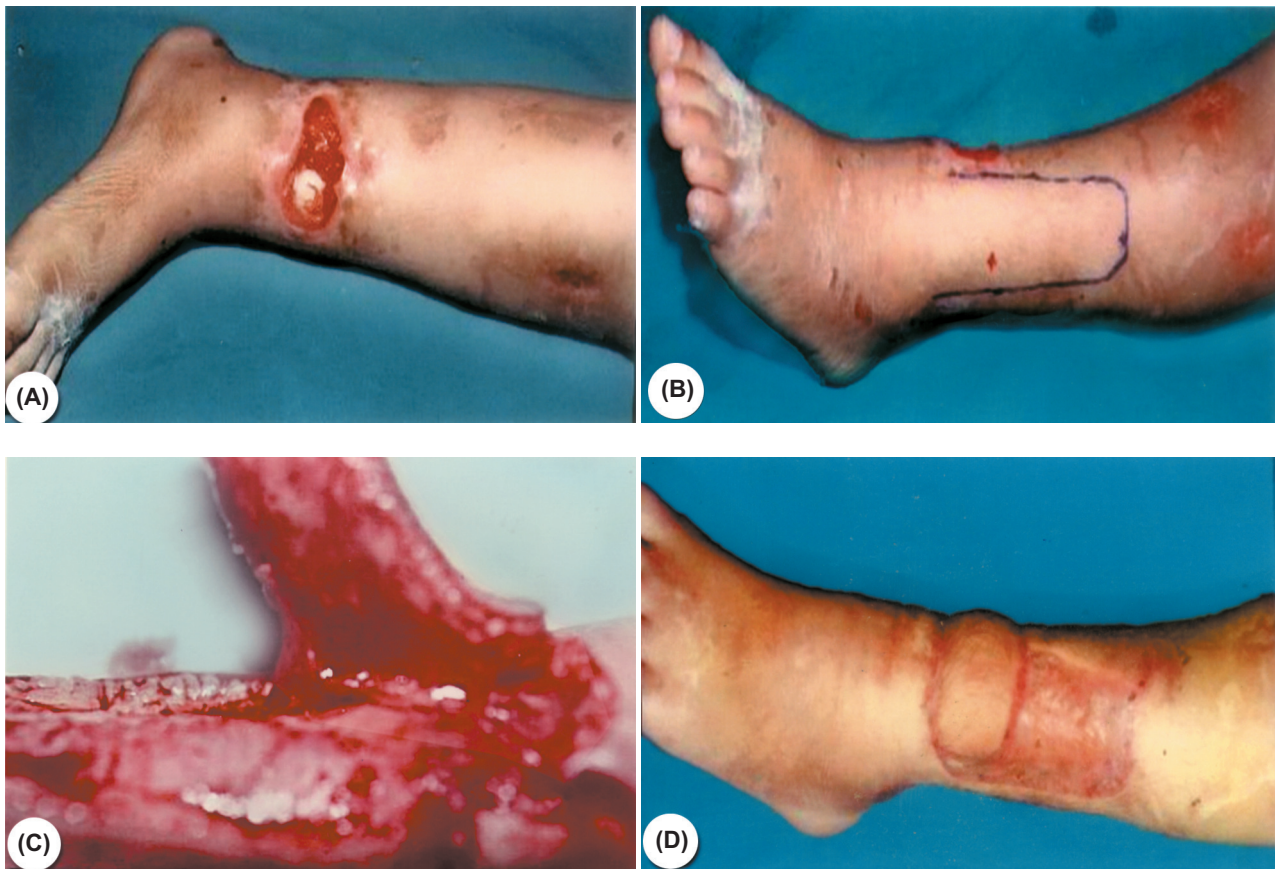

Fig. (1): (A) Post-traumatic soft tissue defect over the distal part of tibia that is exposing the underlying bone in 36-years old woman. (B) Design of the flap. (C) Elevation of the flap. (D) Final result 3 months later.

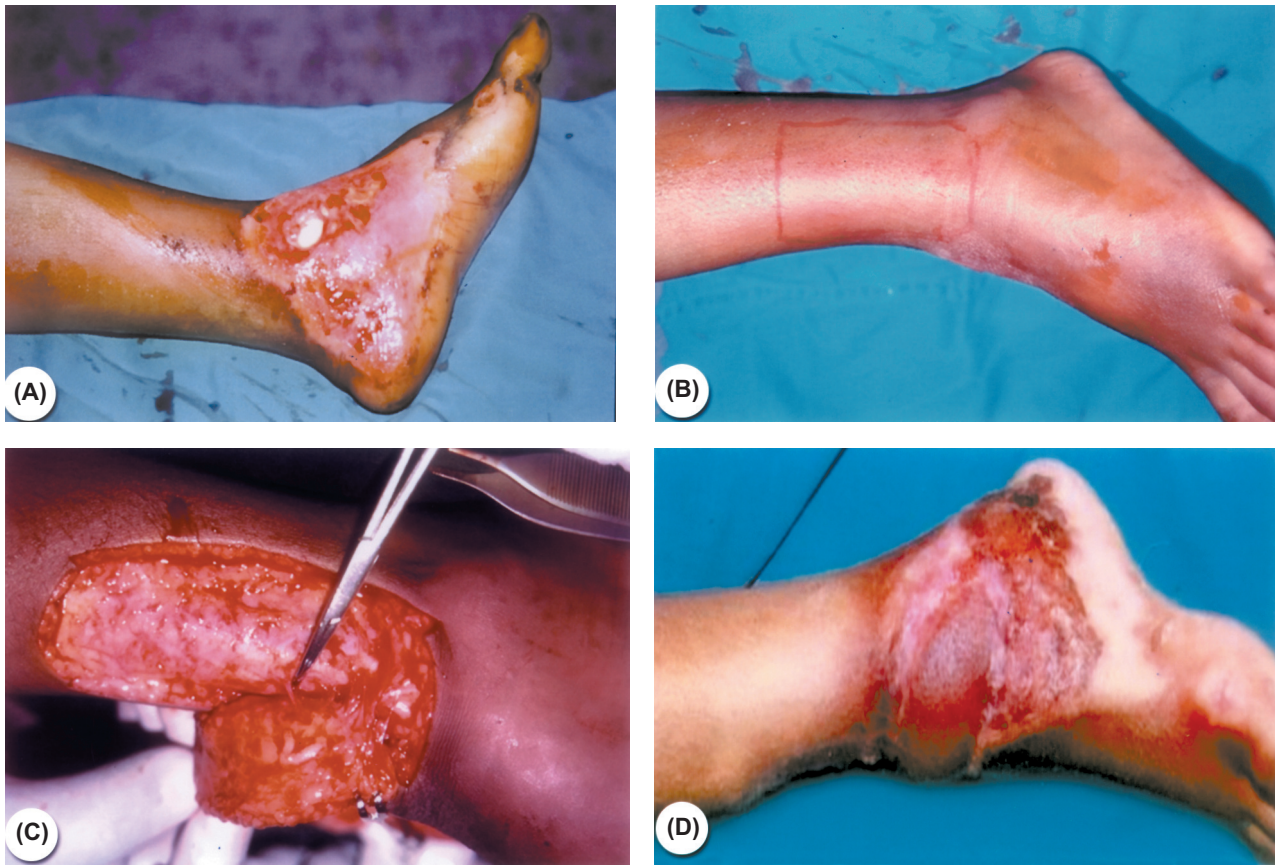


Fig. (2): (A) Post-traumatic soft tissue defect over the medial malleolus that is exposing the underlying bone in 30-years old man. (B) Design of the flap. (C) Elevation of the flap showing perforating branch of peroneal artery. (D) Final result at 7 months.

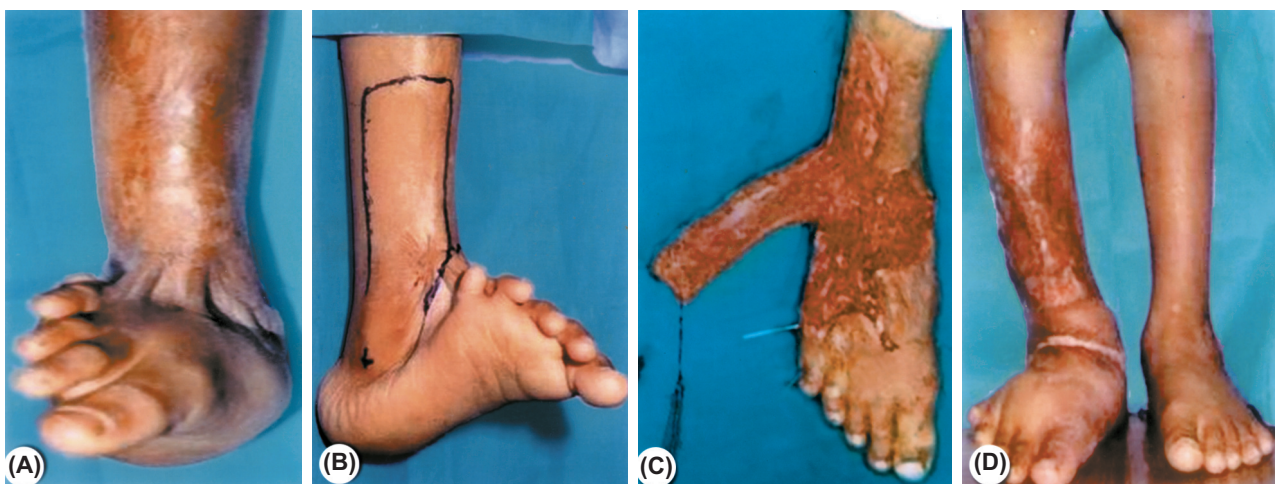


Fig. (3): (A) Post-burn contracture in front of the right ankle in 35-years old woman with dorsiflexion of foot. (B) Design of the flap 5x12cm. (C) Elevation of the distally based flap. (D) Final result after 1 year.

Table (1): Patients data.

Patient	Age	Gender	Etiology	Defect site	Defect Size
1	20	M	Traumatic	Medial malleolus	4x8
2	43	M	Traumatic	Lateral malleolus	3x4
3	2	M	Deep burn	Dorsum of foot	3x5
4	33	M	Traumatic	Distal leg	3x8
5	38	M	Traumatic	Dorsum of foot	4x8
6	37	M	Traumatic	Lateral malleolus	3x4
7	43	M	Deep burn	Front of ankle	5x10
8	57	M	Diabetes	Distal lig	4x10
9	8	M	Traumatic	Lateral malleolus	3x4
10	59	M	Diabetes	Lateral aspect of foot	3x10
11	60	F	Diabetes	Lateral malleolus	4x4
12	60	F	Pressure	Lateral malleolus	3x3
13	30	F	Traumatic	Distal part of tibia	3x6
14	60	F	Pressure	Lateral malleolus	3x4
15	18	F	Deep burn	Front of ankle	5x12
16	36	F	Traumatic	Distal leg	3x11

DISCUSSION

Deep skin injuries of the leg's distal third will certainly leave tendons, vasculonervous bundles, and bones exposed, which must be protected with good quality and good vascularization tissues so as to prevent deep infections and deterioration of such structures. Skin grafts are contraindicated in these circumstances. Muscle flaps, such as soleus and gastrocnemius, are restricted for use to proximal two thirds of the leg [5].

At this level, the well known alternatives are the islands of reverse-flow pedicle flap, microsurgical flap. The disadvantages of free flaps, of course, are that they require a significant operative time (4 to 8 hours) and healthy recipient vessels. In addition, there is the donor-site morbidity to consider and a prolonged hospital stay that usually requires one night in the intensive care unit for flap monitoring. The advantage of free flap reconstruction is that the Achilles tendon is covered with a healthy layer of viable tissue that decreases the risk of tethering and subsequent ulceration [6].

Local and pedicle flaps are also viable options. The lateral supramalleolar flap can be used for a very distal foot defect coverage involving both surfaces. Since its description by Masquelet et al., supramalleolar neurofascio-utaneous flap has become an alternative to sural flap, which covers more distal areas of the foot even better and also acts as a substitute for free flaps in the distal leg, ankle, and foot soft tissue defects [7].

Refinements in the technique increased its reliability and mobility while decreasing donor side morbidity as a distally based flap with a compound vascular pedicle and subcutaneous tissue design. With a pivot point over the tarsal bone, our experience confirmed that a thin, large flap could reach the most distal areas of the foot, and then even turn downwards to cover distal plantar surface. Obvious contour deformity of the donor site is a significant [8].

Flap delay enhanced survival and extended the viable dimensions of lateral supramalleolar flap. Compromised circulation in larger flaps and flaps with vascular variations can be improved by delaying flap transfer to the recipient site for 48 hours following its elevation [9].

The survivability of these flaps can be explained in three ways:

- 1- Adequate perfusion pressure through the incorporated perforators.
- 2- These perforators form rich supra and sub fascial plexus at the level of deep fascia intercommunicating with the supply of adjacent perforators.
- 3- These fascial plexuses are orientated axially, thus making the flap behave like an axial flap [10].

Hence, it is not only the rich plexus of vessels associated with the fascia, but also their orientation that is responsible for survival of flaps of 3:1

length: breadth ratio or more. This is also the basis of perfusion of island flaps [11].

Conclusion:

The simplicity of design and elevation plus their extensive arc of rotation make the supramalleolar flap, reliable in the reconstruction of difficult defects of the lower limb. We have found several advantages of this flap, they include:

- 1- Safety with no sacrifice of major arteries or nerves at donor site.
- 2- Technically easy and quick dissection.
- 3- Reliability, longitudinally oriented axial pattern flap.
- 4- Single stage without microsurgery.

REFERENCES

- 1- Demiri E., Foroglou P., Dionyssiou D., et al.: Our experience with lateral supramalleolar island flap for reconstruction of the distal leg and foot: A review of 20 cases. *Scand. J. Plast. Reconstr. Hand Surg.*, 40: 106, 2006.
- 2- Voche P., Merle M. and Stussi J.D.: The lateral supramalleolar flap: Experience with 41 flaps. *Ann. Plast. Surg.*, 54: 49-54, 2005.
- 3- Masquelet A.C., Beveridge J., Romana C. and Gerber C.:

The lateral supra-malleolar flap. *Plast. Reconstr. Surg.*, 81: 74, 1988.

- 4- Sham E., Choi W.T. and Flood S.J.: Lateral supramalleolar flap in reconstruction of pressure ulcers in patients with spinal cord injury. *Anz. J. Surg.*, 78: 167, 2008.
- 5- De Rezende M.R., Rabelo N.T.A., Benabou J.E., et al.: Covering the distal third of the leg with pedicled perforating vessels patches. *Acta. Ortop. Bras.*, 16: 223, 2008.
- 6- Attinger C.E., Ducic I., Hess C.L., et al.: Outcome of skin graft versus flap surgery in the salvage of the exposed achilles tendon in diabetics versus non diabetics. *Plast. Reconstr. Surg.*, 17: 2460, 2006.
- 7- Touam C., Rostoucher P., Bhatia A. and Oberlin: Comparative study of two series of distally based fasciocutaneous flaps for coverage of the lower one-fourth of the leg, the ankle, and the foot. *Plast. Reconstr. Surg.*, 107: 383, 2001.
- 8- Agir H., Sen C. and Onyedi M.: Extended Lateral Supramalleolar Flap for Very Distal Foot Coverage: A Case With Arteriovenous Malformation. *Ankle Surg.*, 46: 310, 2007.
- 9- Ahmed S.K. and Hashmi P.M.: Delayed supramalleolar flap: An innovative technique for enhanced viability. *J. Ayub Med. Coll. Abbottabad*, 3: 17, 2005.
- 10- Bhattacharya V., Watts R.K. and Reddy G.R.: Live demonstration of microcirculation in deep fascia and its implication. *Plast. Reconstr. Surg.*, 115: 458, 2005.
- 11- Bhattacharya V., Reddy G.R., Goyal S. and Kumar U.: Skeletonised retrograde distal perforator island fasciocutaneous flaps for leg and foot defects. *J. Plast. Reconstr. Aesth. Surg.*, 60: 892, 2007.